



PATIENT

Gipper Tracy

SPECIES

Canine

BREED

Lab

SEX

Female Spayed

AGE

12.8 years

WEIGHT

92lbs

INTERPRETED BY

Maggie Machen Lamy,
DVM, DACVIM
(Cardiology)

IMAGING PERFORMED BY

Potomac Mobile
Veterinary Ultrasound

HOSPITAL NAME

Banfield Pet Hospital
Leesburg Village

REFERRING VET

Dr. Jarrett

INVOICE

25193

DATE

7/7/22

PRESENTING CLINICAL SIGNS

History: Has Cushing's. Left adrenal gland tumor. Heart murmur, grade 3-4/6. Not eating as much, panting, and coughing more. Was recently started on Lasix 50mg BID and has improved clinically
-Current medications: Lasix, Galliprant, Gabapentin, Tramadol, Cosequin, and Denamarin
-Abnormal PE/Chem/CBC/UA Results: U/A: WBC TNTC, Epithelial Cells 1-2, Cocci 1-2.

ECHOCARDIOGRAM FINDINGS

2D, m-mode, color flow and doppler imaging is available. Diffuse thickening of mitral valve leaflets with minimal prolapse into the left atrial lumen. Severe eccentric mitral regurgitation with severe left atrial dilation. Normal MR velocity. Mild LV dilation with mild myocardial dysfunction. The tricuspid valve appears thickened with moderate TR. Normal velocity. Mild right heart enlargement. The pulmonic and aortic valves are normal in morphology and mobility. Normal aortic and pulmonic outflow velocities with laminar flow. No AI/PI. No pericardial or pleural effusion noted. No obvious cardiac masses.

CARDIAC CHART

CANINE CARDIAC PARAMETERS	MR VMAX (m/s)	TR VMAX (m/s)	LA/AO (Boon method)	LA/AO (Heart Base; Swe)	FS (%)	EF (%)	EPSS (cm)
NORMAL PARAMETER	4.5-5.5	<2.7	1.3	<1.6	28-40	40-100	<0.6
PATIENT	4.8	2.5	NM	2.5	24	46	0.9
CANINE CARDIAC PARAMETERS	HR (BPM)	AV VMAX (m/s)	PV MAX (m/s)	BODY WEIGHT (kg)	LA 2D short axis Base view (cm)	LVIDd Avg; 2D and m-mode short axis (cm)	LVIDs Avg; 2D and m-mode short axis (cm)
NORMAL PARAMETER	50-100	0.7-1.7	0.7-1.6	BELOW	BELOW	BELOW	BELOW
PATIENT	88	0.8	0.7	41.7	5.2	5.7	4.4
*Normal chamber parameters expressed as a mean value (SD)				3	1.27 (5.3)	2.46 (2.46)	1.36 (5.5)
BODY WEIGHT DEPENDENT PARAMETERS				5	1.40 (4.5)	2.74 (5.2)	1.60 (4.7)
<i>*Note: All measurements based upon multi-modal images and methods. An average value is reported.</i>				10	1.50 (3.8)	3.27 (3.5)	2.06 (3.1)
				15	1.83 (2.0)	3.71 (2.4)	2.43 (2.1)
				20	2.02 (1.9)	4.14 (2.2)	2.80 (2.0)
				25	2.18 (2.4)	4.48 (2.9)	3.10 (2.5)
				30	2.33 (3.3)	4.83 (3.9)	3.39 (3.4)
				35	2.48 (4.3)	5.17 (5.0)	3.69 (4.5)
				40	2.62 (5.2)	5.48 (6.1)	3.96 (5.4)
				50	2.88 (7.1)	6.07 (8.3)	4.46 (7.4)

INTERPRETATION OF THE FINDINGS & FURTHER RECOMMENDATIONS

The cause of the murmur is chronic degenerative valve disease causing severe mitral and moderate tricuspid regurgitation. Severe left atrial enlargement indicates the risk for spontaneous congestive heart failure is elevated. Mild LV dysfunction is noted, which is common in large breed dogs with CVD. No additional issues are identified.

In light of the clinical signs, response to Lasix and severity of disease on echocardiogram, the diagnosis of congestive heart failure is supported, and continued medications are warranted lifelong as below. Monitoring of sleeping respiratory rates will be paramount to screen for



PATIENT

Gipper Tracy

SPECIES

Canine

BREED

Lab

SEX

Female Spayed

AGE

12.8 years

WEIGHT

92lbs

INTERPRETED BY

Maggie Machen Lamy,
DVM, DACVIM
(Cardiology)

IMAGING PERFORMED BY

Potomac Mobile
Veterinary Ultrasound

HOSPITAL NAME

Banfield Pet Hospital
Leesburg Village

REFERRING VET

Dr. Jarrett

INVOICE

25193

DATE

7/7/22

congestive heart failure at home. Cough suppression to improve QOL can also be considered (hydrocodone, 0.2-0.4mg/kg up to q4-6h PRN) for any residual mechanical cough in the face of normal sleeping respiratory rates. The average survival time of canine patients with active pulmonary edema is 8-9 months on medications, however they generally are able to maintain a good quality of life for that period. Patient will always be at risk for recurrent CHF, development of arrhythmias/LA tear, syncope and/or sudden death in the future.

Omega fatty acid supplementation and mild salt restriction may also be of some long-term benefit. Monitor for acute progression of the cough, labored breathing, exercise intolerance or collapse episodes in the future.

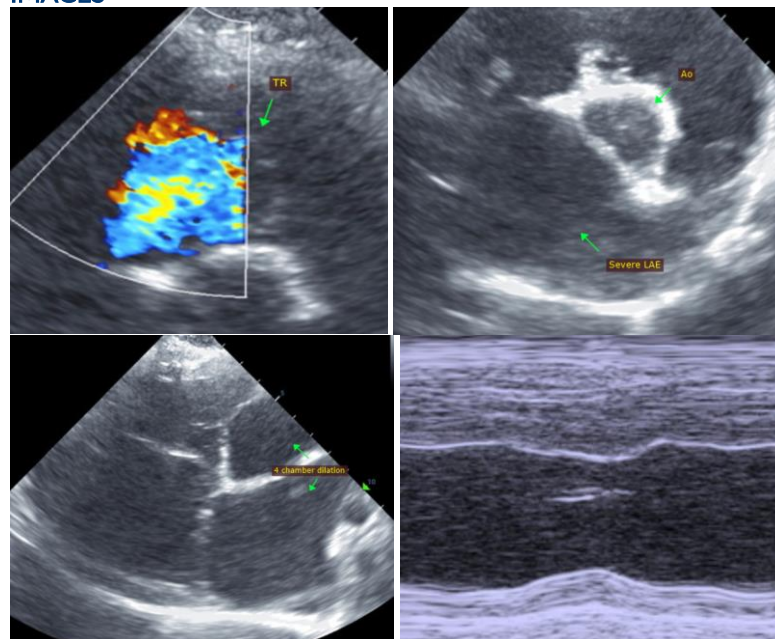
PLAN

Institute Pimobendan 0.3mg/kg PO q12h. Institute Furosemide 1-2mg/kg PO q12h. Institute spironolactone 1-2mg/kg PO q12h.

Monitor SRRs at home. Monitor renal values and BP in 10-14 days, then every 3-4 months while on diuretics. If doing well and BP >130mmHg, institute ACEI 0.5mg/kg PO q12h. Consider hydrocodone if needed for QOL.

Recommend conservative monitoring with a recheck echocardiogram in 6 months, sooner if any development of associated clinical signs occurs in the interim.

IMAGES



The information and recommendations provided are based on the images presented by the referring veterinarian. No evaluation can be communicated regarding pathology that was not visible in the image/video clips provided.

Thank you for this referral. This report was generated using transcription software, and minor dictation errors may be present. If the clinical or image interpretation does not parallel your findings



PATIENT

Gipper Tracy

or if I can be of any further assistance, please contact me.

SPECIES

Canine

Maggie Machen Lamy, DVM

Diplomate of the American College of Veterinary Internal Medicine (Cardiology)

info@sonopath.com

BREED

Lab

SEX

Female Spayed

AGE

12.8 years

WEIGHT

92lbs

INTERPRETED BY

Maggie Machen Lamy,
DVM, DACVIM
(Cardiology)

**IMAGING
PERFORMED BY**

Potomac Mobile
Veterinary Ultrasound

HOSPITAL NAME

Banfield Pet Hospital
Leesburg Village

REFERRING VET

Dr. Jarrett

INVOICE

25193

DATE

7/7/22